Outcomes of combined Baerveldt glaucoma implant and Trabeculectomy with Mitomycin C in patients with advanced glaucoma with high risk of primary Trabeculectomy failure

Henrietta Ho, Saurabh Goyal
Department of Ophthalmology, St Thomas' Hospital, London, United Kingdom

Contact – saurabh.goyal@gstt.nhs.uk

Introduction

The management of advanced glaucoma is challenging, and requires aggressive and early intraocular pressure (IOP) lowering.[1] Early flow restriction is needed to mitigate against hypotony in the valve-less Baerveldt glaucoma implant (BGI), but leaves IOP at preoperative high levels and may result in progression in patients with advanced field loss.[2]

Purpose

To describe our experience and outcomes with combined BGI and trabeculectomy with mitomycin-C (MMC).

Methods

•Consecutive patients had combined BGI and trabeculectomy with MMC with a minimum follow-up period of 1 year.
•Risk factors for primary trabeculectomy failure included Afro-Carribean race, severely injected or immobile superior conjunctiva.
•Advanced glaucoma included progressive field loss (MD < -12dB) or fixation-threatening central field defects.

Surgical technique

- A fornix-based superotemporal conjunctiva peritomy with a temporal relaxing incision is made.
- Subtenon application of MMC soaked (0.4mg/ml) sponges is applied for 4 minutes, then irrigated.
- BGI is inserter under the muscles and is sutured to sclera 8-10mm from limbus with 9-0 prolene sutures.
- An intra-luminal Supramid stent suture (braided 3-0 nylon) is passed.
- BGI tube is trimmed and inserted 2mm from the limbus (Fig. 1A) along a track created using a 25-gauge needle.
- The Supramid suture is retracted along the tube until flow is first noticed, and a 10-0 nylon ligating suture is tied to stop all flow.
- Double-layer pericardial patch (Tutoplast) is sutured over the tube.

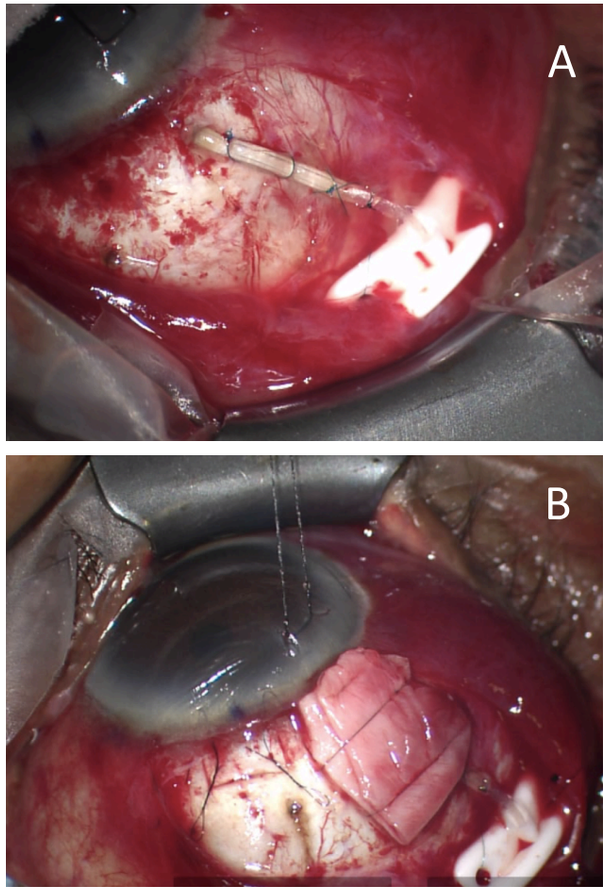

Figure 1: *Right supero-temporal placement of tube, secured with 9-0 prolene (A). Location of trabeculectomy flap in relation to tube placement (B).*

- The distal end of the Supramid suture is tucked into the inferior fornix to facilitate removal in clinic.
- A 2 x 2 mm scleral flap nasal to the BGI is created (Fig. 1B), followed by sclerostomy and iridectomy.
- 2 pre-placed releasable 10-0 nylon sutures re-approximate the flap to ensure no flow at equilibrium, and flow only on pressure on the flap.
- Conjunctiva is then closed with 10-0 nylon.

Postoperative care following trabeculectomy failure

- Trabeculectomy releasable sutures are removed as needed.
- Glaucoma eye drops can be used if IOP is inadequately controlled
- Ligating suture lysis is performed after at least 6 weeks post-operatively
- Removal of supramid (ROS) delayed at least 3 months post-operatively

Failure

- IOP > 14mmHg or not reduced by 20% below baseline on 2 consecutive visits after 3 months
- Need for additional glaucoma surgery
- Loss of light perception vision

Results

- Majority of patients were Afrocarribean (n=24) and 4 were Caucasian.
- 25 patients had POAG, 1 had NTG, 1 had PACG and 1 had uveitic glaucoma.
- 50% of patients were male.
- Trans-scleral cyclodiode laser was performed for additional IOP lowering in 2 eyes >4 years after surgery.
- Although one patient had IOP of >14 on two visits, his IOP improved subsequently with ROS and eye drops.
- There were no patients who developed suprachorodial hemorrhage, tube exposure or motility disorder during the follow-up period.

Table 1: Clinical characteristics of patients

Cliinical Variables	Pre-operative		Post-operative	
	N = 28	Range	N = 28	Range
VA	0.2 (0.3)	-0.2 to 0.8	0.4 (0.6)	-0.2 to 2.3
IOP	22.6 (7.9)	13.0 to 42.0	11.0 (3.2)	6.0 to 20.0
Number of drops	3.5 (0.6)	2 to 4	1.3 (1.4)	0 to 4

Presented as mean (SD) and mean (%), where appropriate.
Post-operative visit refers to last follow-up visit.

Table 2: Early post-operative complications

Complications	N	Details
Tube Obstruction	1	Resolved with iridoplasty
Endophthalmitis	1	Vitreous tap and injection of antibiotics. No additional surgery.
Hypotony	1	Conservative management
Exposed supramid suture	3	Supramid suture trimmed and tucked back under conjunctiva

Discussion

- In the eyes that had cyclodiode, IOP remained controlled beyond 5 years post-operatively.
- Hypotony developed in a patient with previous phaco/XEN implant and subsequent external cyclodiode, likely from low aqueous production. This resolved spontaneously without further surgery.
- Reports on outcomes of combined surgery for refractive glaucoma are scarce and limited to small numbers.[3,4,5] Our success rates are comparable to the largest series published, with a cumulative success of 91% at one year.[3] Opening of the tube was needed in 47% of their patients over 34 months compared to 71% of our cohort after 28 months, suggesting a possible greater tendency for failure in our patients. This may in part be explained by the racial differences in our cohorts.
- Our success rates are similar compared to the 1-year outcomes from the landmark primary tube versus trabeculectomy study, with much lower complication rates.[6]

Conclusion

In spite of a low IOP (≦14mmHg) benchmark for success, combined BGI and trabeculectomy with MMC allows excellent early and mid term IOP control in patients with advanced glaucoma. Complications were low and similar to those expected with tube and trabeculectomy.

Figure 2: IOP and medication trend during 1 year follow-up

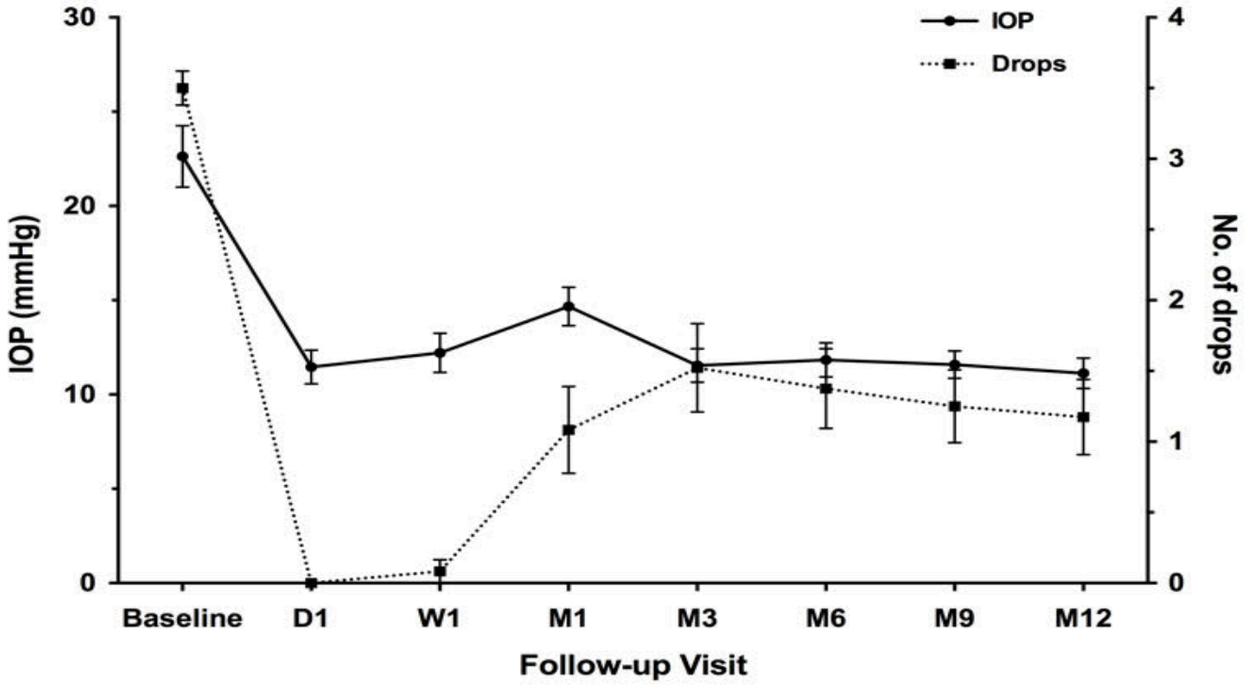

References

[1]Peters D, et al. Factors associated with lifetime risk of open-angle glaucoma blindness. Acta Ophthalmol 2014;92:421-5.

[2]Forchheimer I, et al. Basline mean deviation and rates of visual field change in treated glaucoma patients. Eye (Lond). 2011 25:626-32.

[3]Budenz DL, et al. Combined Baerveldt glaucoma drainage implant and trabeculectomy with mitomycin C for refractory glaucoma. J Glaucoma 2002;11:439-45.

[4]Hamard P, et al. Molteno implant and refractory glaucoma. Evaluation of postoperative IOP control and complications with a modified surgical procedure. J Fr Ophthalmol. 2003;26:15-23.

[5]Hill RA, et al. Trabeculectomy and Molteno implantation for glaucomas associated with uveitis. Ophthalmology 1993;100:903-8.

[6]Gedde SJ, et al. Treatment outcomes in the primary tube versus trabeculectomy study after 1 year of follow-up. Ophthalmology 2018;125:650-63.