Clinical observation of deep sclera and Descemet membrane incision for glaucoma

Zhao Xiuqin[1], Liu Luhong[2], Zhang Jinsong[1]

[1] Shenyang Excllence Aier Eye Hospital, 110000, China; [2]Department of ophthalmology, people's hospital of guangxi zhuang autonomous region,Nanning, 530021,China,

Abstract: Objective Northeast China is a high incidence area for glaucoma. With the improvement of current antiglaucoma operation technique,the successful rate of the control of intraocular pressure (IOP) is significantl increased. However,the scar formation of filtration bulb after surgery is still a main cause leading to a failure outcome. In current investigation, we evaluated the clinical outcome of deep sclera cauterization and Descemetic membrane incision in glaucoma. **Methods** 1.clinical data From 1997 to 2013, we used deep sclera incision and cauterization and Descemetic membrane incision, in this way, we finished and followed them of 101 examples (128 eyes). 2.Operation Methods: Ponventional methods are basement of the cojunctival flap for limbal. With limbal basal half of the sclera made,the thickness of it is the same 4.0mm×6.0mm,anatomy until transparent cornea in 1.0 mm. Inside the transparent cornea 0.5mm, making a crosscutting of 1mmx4mm its depth touches dismantles membrane, with a burning device posterior lip of cauterize incision site ,the depth of the burning with a burning is until place dismantle membrane the degree of burning isn't too heavy. It is advisable to strength to meet sclera surface mild contration. When burning, it is better with cotton insulation(Fig 1),Burning incision is 4mm in length, The width is 1mm to burn fully the both sides of the incision .Then, to burn the wound under the sclera flep espelially,

to burn the part of the blood vessels, make it scabby(Fig 2),in order to make the aqueous humor flow out smoothly. in the conjuctival reset where sew a needle. **3.**Post-Proessing after operation. In all cases, the intraocular pressure, visual acuity, filtering bleb, anterior chamber depth, pupil, lens, etc. were observed and recorded in detail on the 1st, 2nd, 3rd, 5th, and 7th days after the operation.Regular follow-up after discharge.**4.**situation after the operation Successful operation standard of judging.**1)**According to the rate of successful operation of Kim's and others calibration, if the vision of the operation has varying degree increase, the intraocular pressure is controlled in 10-21 mmHg, and the glaucoma medication is not used, the operation will be successful. If the vision of the operation continues falling, the intraocular pressure is over 21mmHg,the operation will be not successful. **2)**The

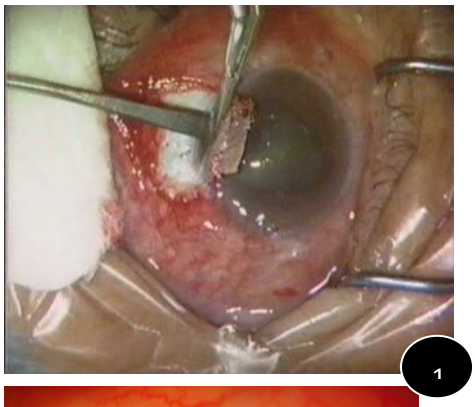

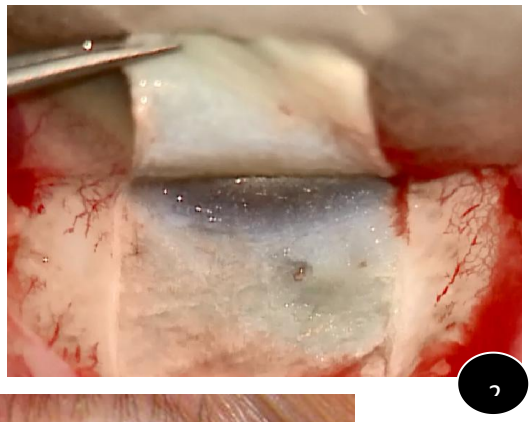

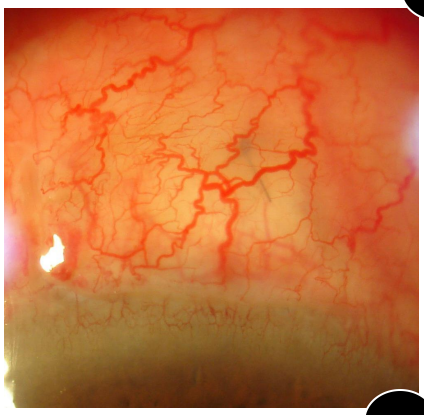

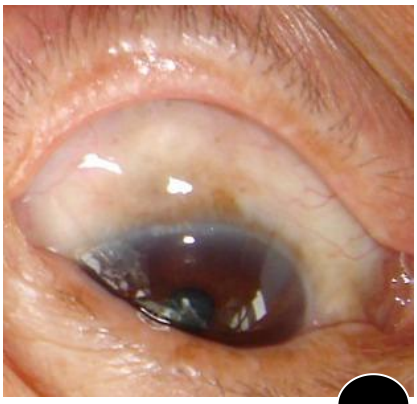

standard of forming filtering bleb:Filter bleb formation following conventional glaucoma surgery. 3)Follow-up situation. The follow-up time was generally 1, 3, and 6 months after discharge, 1 year, 2 years, 3 years, and 5 years. The shortest was 12 months and the longest was followed up for 10 years (the patient's current vision was maintained at 0.6). (Fig 4) The average follow-up time was 29.6 months.

Results 1. situation of intraocular pressure . The mean IOP was lowered from preoperation (74. 94±11.26)mmHg to postoperation (18.11 ± 3.40) mmHg in acute close-angle glaucoma (t = 35. 832 2, P < 0.05) ; (37.94 ± 5.63) mmHg versus (16. 54 ± 1.84) mmHg in chronic close-angle glaucoma (t = 23. 134 5, P < 0. 05) ; (32.48 ± 4. 17) mmHg versus (I6. 54 ± 3.15) mmHg in primary open-angle glaucoma (t = 9. 645 3 ,P < 0. 01) ;(46. 76 ±7. 12) mmHg versus (18.09 ±2. 21) mmHg in secondary glaucoma (t = 8.599 2, P< 0. 01) and (43.86 ± 2. 13) mmHg versus (18.31 ± 1. 57) mmHg in refractory neovascular glaucoma (t =4. 773 4 ,P < 0. 05) . Follow-up until 24 months, the different intraocular pressures were compared before and after the operation, the differences were obvious meaning[Table 1]. 2. situation of vision. The vision of the different glaucoma patients is compared before and after the operation[Table 1]. the vision of the team after the operation is all certain improvement recently, the patients of a follow-up ten year , their visions were 0.6, the vision of follow-up glaucoma patients from101 examples(128eyes) after the operation is tested(Table 2).

Filtering bleb: Of 128 eyes, 59 eyes were formed into filtering bleb of Type Ⅰ after the operation, 56 eyes were formed by type II filtering bleb, and 13eyes were formed by type III filtering bleb, the rate formed

of 89.84%.The filtering bleb appeared diffusion shape and a little elevated filtering bled, the formas were good.fig 4. The mean vision acuity was significantly changed before and after operation (P < 0.05). No severe intraoperative and postoperative complications were found.

Table1. IOP and Vision before and after the operation in glaucomatous eyes.

Glaucoma types	n	IOP(mmHg)		Vision acuity	
		Pre-op	Post-op	Pre-op	Post-op
Acute close-angle	53	74.94±11.26	18.11±3.40[b]	0.0785±0.06	0.2521±0.14[b]
Chronic close-angle	41	37.94±5063	16.54±1.84[b]	0.1346±0.08	0.1735±0.11[b]
Primary open angle	22	32.48±4.17	16.54±3.15[c]	0.1532±0.09	0.1829±0.12[b]
Secondary	8	46.76±7.12	18.09±2.21[c]	0.1237±0.03	0.1931±0.17[b]
Reconday neovascular	4	43.86±2.13	18.31±1.57[b]	0.2316±0.05	0.2531±0.07[b]

[b]$P<0.05$,[c] $P<0.01$ vs respective Pre-op value (**Paired** *t*test)

Table 2 Visual acuity of follow-up examination in glaucomatous eyes

Glaucoma types	Vision acuity							
	LP%	HM%	FC(%)	0.02-0.05%	0.06-0.1(%)	0.2-0.5(%)	0.6-1.0(%)	Tota
Acute close-angle	0(0)	0(0)	1(1.89)	1(1.89)	4(7.55)	33(62.26)	14(26.41)	53
Chronic .close-angle	0(0)	0(0)	2(4.87)	2(2.5)	2(4.87)	29(70.73)	7 (19.51)	41
Primary open-angle	0(0)	0(0)	0(0)	0(0)	2(18.2)	15(68.18)	5(25)	22
Secondary	0(0)	0(0)	0(0)	1(12.5)	01(12.5)	6(75)	0(0)	8
Refractory.neovascular	0(0)	0(0)	0(0)	1(25)	01(25)	1(50)	0(0)	4

LP: light preceptor; HM:hand move; FC:finger count

Conclusion The study has been observed in clinic for 16 years[6].Its advantages are:1.after cutting open deep scleritic, then scorching the cut, finally use descemetic membrane incision . After operation, blocking-filtration canals and filtration bleb scar do not happen and long-term effect is steady. 2.while operation ,do not cut open full-thickness trabecular meshwork, after operation, the functional recovery is good and shallow anterious chamber does not happen. In early time, filration bleb forms well. 3. while operating, we do not use MMC to advoid effectively incidence of thin wall-filtration bleb and endoophthalmitis. Anyway, A safe and effective result is observed in the deep sclera and Descemetic membrane incision in the treatment of various glaucoma.

Key words:
Glaucoma Surgery; Deep sclera and Descemetic membrane incision; Long-term effect

Email：zhaoll6611@163.com
wechat:cyzxq8656,
Cell Phone:(086)13674135963